

Superficial Dorsal Ulnar Artery Flap for Hand and Wrist Coverage

MAGDY ABD AL MOKTADER, M.D.

The Department of Plastic and Reconstructive Surgery, Faculty of Medicine, Al-Azhar University.

ABSTRACT

Reconstruction of soft tissue defects around the wrist and hands with exposed tendons, joints, nerves and bone represents a challenge to the plastic surgeons, and such defects necessitate flap coverage to preserve hand functions and to protect its vital structures. There are very limited options for flaps to cover them. When underlying structures are exposed, the split skin graft has a limited role, the need for flap cover can be met either by a local flap, distant flap or free flap. The field of reconstructive surgery has taken a significant leap forward with the introduction of perforator flaps. The primary advantage of perforator flaps is the minimization of donor site morbidity. Perforator-based surgery has added a new dimension to the field of reconstructive surgery. We use the distally-based island superficial dorsal ulnar artery perforator flap based on dorsal ulnar artery for wrist and hand defects and present our results.

INTRODUCTION

The soft tissue reconstruction of the hand poses a formidable challenge to the plastic and reconstructive surgeons. Durable and stable coverage of soft tissue defects of hands with a cutaneous flap seems to be an ideal solution. The paucity of local or regional flaps that are thin, pliable, and large enough, forces the surgeon to perform incomplete excisions and use skin grafts with their inherent drawbacks and suboptimal outcomes. The dorsal ulnar artery fasciocutaneous flap was first described by Becker and Gilbert in 1988, perfused by the ascending branch of the dorsal ulnar artery, one of the major branches of the ulnar artery in the distal forearm [1-4]. The importance of this flap lies in the possibility of mobilization of tissue for reconstruction of the hand without losing a major vascular axis. The dorsal ulnar artery fasciocutaneous flap can be raised as a hinge (peninsular), or as a true island flap. In the present study, we evaluate the applications of "superficial dorsal ulnar artery flap" in reconstruction of soft tissue defects of hand and wrist.

Anatomy:

Becker The pivot point of the flap is approximately 4cm proximal to the pisiform bone in a line

drawn between this bone and the medial epicondyle of the humerus; that is the position of the dorsal ulnar artery origin. Near the pivot point the flap is raised in between the FCU and ECU tendons. The dissection begins at the apex of the flap. The flap is raised with the fascia over the muscle belly of the FCU. Then it gives off three collateral branches. The proximal branch enters the flexor carpi ulnaris muscle. The distal branch is the pisiform artery. The medial branch is the fasciocutaneous branch which divides into ascending and descending branches. The perforators are the branch of this medial branch of the dorsoulnar vascular network. The dorsoulnar artery has two committing veins represent the venous drainage of the flap. These were first reported by Becker and Gilbert [2]. They demonstrated that the dorsal ulnar vessel was constant on 100 fresh forearms, with a diameter of 1-3mm, and they also reported the absence of the dorsal branch of the ulnar artery in two of 100 dissections. According to the anatomic studies performed by Bertelli and Pagliei [3], the dorsal branch was a branch of the anterior interosseous artery in 2 of 26 dissections [5,6,7].

Material AND METHODS

Operative technique:

Dorsal ulnar artery was localized with the help of Doppler examination. Operation was done under general anesthesia or axillary block with tourniquet control and loupe magnification. Soft tissue defect of hand was created after scar excision in case of post-burn contracture or debridement in case of traumatic wound, and flap was designed accordingly. The flap was raised as an island flap. The dissection started from the ulnar side of the wrist and forearm from proximal to distal including the deep fascia. The pedicle was exposed by retracting the flexor carpi ulnaris radially. The pedicle emerged from the ulnar artery 2 to 5cm proximal to the pisiform. Care was taken to preserve the dorsal branch of the ulnar nerve. The dorsal ulnar

artery was dissected at its origin from the ulnar artery which permitted 180° rotation of the flap. The space between the defect and the pedicle of the flap was incised, and a sulcus was created by excision of subcutaneous tissue. Tourniquet was then released, hemostasis was achieved and the flap was transferred to the defect. The subcutaneous pedicle of the flap was skin grafted to avoid tension.

The donor site was closed primarily in three patients after undermining the skin flaps. These were less than 5cm wide. Larger donor defects were skin grafted. Non-adherent dressing was applied and the hand was immobilized in neutral position for about a week. Active and passive physiotherapy followed and continued for a period of three months thereafter.

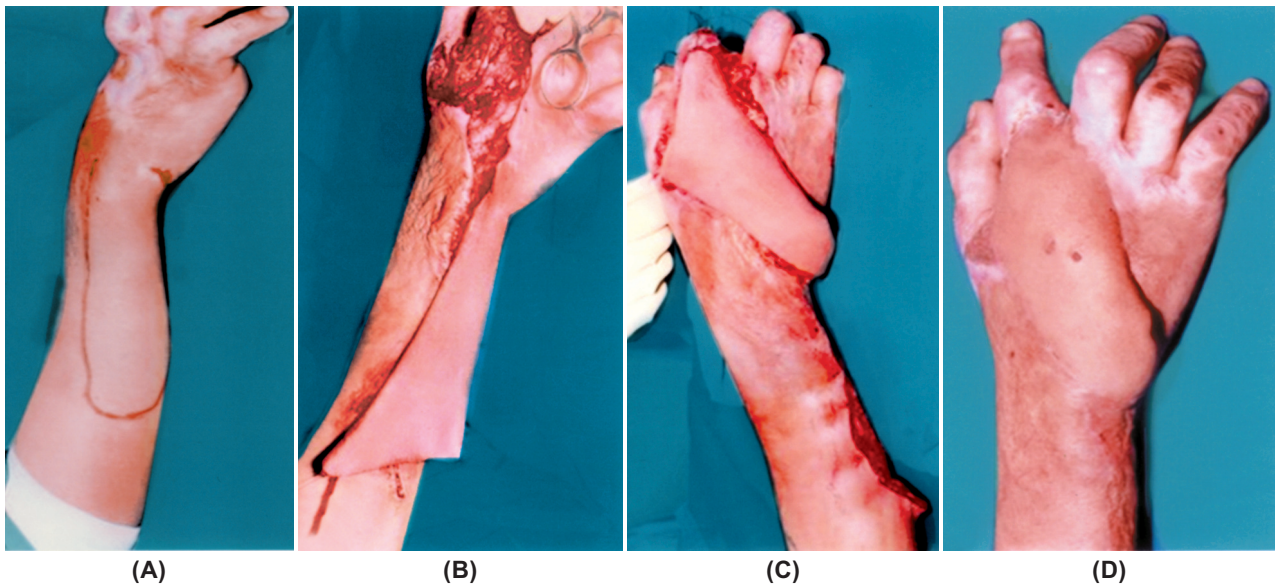


Fig. (1): (A) Post-burn contracture on dorsum of the right hand in 20-years old Woman with design of the flap 6x16cm. (B) Elevation of the flap. (C) The flap cover the defect (D) Final result after 9 months.

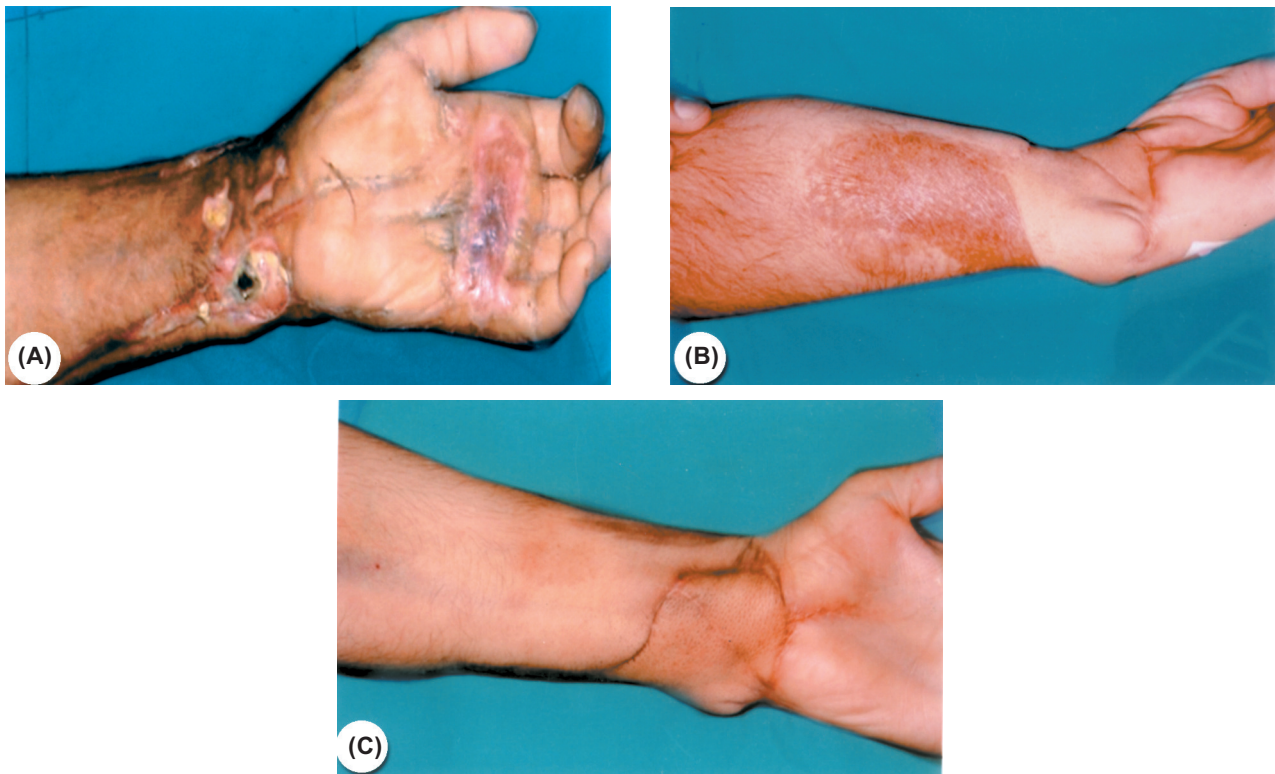


Fig. (2): (A) Post electrical burn contracture on back of the left knee in a 25-year old man with design of the flap 7x16cm. (B) The flap cover the defect after 6 months. (C) Final result after 18 months with a good appearance without bulk.

RESULTS

Six cases were treated with this flap, their ages were between 5-60 years. Two cases with postburn contracture of the hand and first web, two cases with acute injury and skin loss, one case with post electrical burn lost skin on the volar aspect of the wrist, last case was post surgical contracture of the wrist after cut wrist surgery. One case with distal two centimeter superficial desquamation which healed spontaneously, another five cases healed uneventfully. Donor site less than 5cm closed primarily after dissection of both edges of the donor area, donor more than 5cm were grafted (Figs. 1,2).

DISCUSSION

Soft tissue defects of hands require early coverage so that physiotherapy can be done as early as possible. Coverage is necessary to replace missing skin and to protect exposed structures. Various flaps have been described. The reverse radial island flap or reverse ulnar island flap have the disadvantage of sacrificing a major vascular axis. Distant flaps require long immobilization and are very discomforting. They are bulky and need thinning by yet another procedure. Free flaps require microsurgical skills and are lengthy procedures. The dorsal ulnar artery fasciocutaneous flap was first described by Becker and Gilbert, as a local flap for covering small skin defects of hand [1,2]. The disadvantages of dorsal ulnar artery flap are the retrograde venous drainage and the relatively small defects which can be covered. Antonopoulous et al., designed flaps up to the maximum theoretical limit of the territory supplied by the dorsal ulnar artery (20cm long by 9cm wide) [8]. They used the longer length of flap to cover the defects on the radial border of the hand and wrist. Although local flaps are usually limited in size and mobility by the size and location of the defect, however if feasible, they offer relatively simple and safe wound coverage, spare the distant donor site for further reconstruction, and do not interfere with the patient's activities and physical therapy. The deepithelialized turnover flap [9,10] represents a reliable method, but there is donor site morbidity in terms of aesthetics and a large amount of skin graft is needed to resurface the wound. The local adipofascial turnover flap [11,12] represents a reliable and simple technique for reconstruction if the surrounding soft tissue is available, but this is not always possible because of the limitation in terms of size and degree to which the flap can be raised. The posterior interosseous artery distally-based flap is suitable for the coverage of dorsal skin defects of

the hand but can also be used for the volar aspect of the distal forearm and wrist and avoids interference with the two main arteries of the forearm. The dissection of the vascular pedicle, however, is frequently quite complex and tedious. It is necessary to have local healthy tissue around the wrist joint. If the distal perforators of the posterior interosseous artery and its branches are injured, the flap should be abandoned [13,14].

The dorsal ulnar artery flap is a well-established technique for repairing small to medium sized defects of the dorsum of the hand and proximal ulnar defects of the palm. The dorsal branch of the ulnar artery is reliable [3]. Testut and colleagues constantly found this vessel in their dissections, other authors reported the absence of this vessel in 2 of 100 and in 3 of 50 forearm dissections [2,15,16]. In this study, we have tried to explore the potential advantages of the dorsal ulnar artery island flap so that we can recommend it in various challenging situations for covering the soft tissue defects of hand. The longer length of the flap allowed covering the defects of the wrist, palm, radial border of the hand and the first web space. The length of the flap is determined by the major axis of the tissue loss but can extend up to 20cm, early use of a flap with single-stage procedure that can provide well-vascularized flap coverage at the earliest, offers the best possible functional results with early rehabilitation, decreasing morbidity and hospital stay compared with other forearm flaps. Our flap has a number of advantages. Distally-based island ulnar artery perforator flap is a local flap, quick, easy to manage and aesthetically good. It is based on one or occasionally on two perforators. The flap is distally based which imports undamaged tissue into the primary defect and allows secondary defect closure easily. Islanding the flap facilitates the arc of rotation and avoids the pedicle kink when the flaps are turned 180° and allows more distal reach of the flap, it therefore allows easier inset and has a better contour. There are some drawbacks with this technique: Scar formation at the donor site, and transient numbness at the donor site.

REFERENCES

- 1- Becker C. and Gilbert A.: The cubital flap. *Ann. Chir. Main*, 7: 136-42, 1988.
- 2- Becker C. and Gilbert A.: The ulnar flap-Description and applications. *Eur. J. Plast. Surg.*, 11: 79-82, 1988.
- 3- Bertelli J.A. and Pagliei A.: The neurocutaneous flap based on the dorsal branches of the ulnar artery and nerve: A new flap for extensive reconstruction. *Plast. Reconstr. Surg.*, 101: 1537-43, 1998.

- 4- Holeyich-Madjarova B., Paneva-Holeyich E. and TopKarov V.: Island flap supplied by the dorsal branch of the ulnar artery. *Plast. Reconstr. Surg.*, 87: 562-6, 1991.
- 5- Inada Y., Tamai S., Kawanishi K., Omokawa S., Akahane M., Shimobayashi M., et al.: Free dorsoulnar perforator flap transfers for the reconstruction of severely injured digits. *Plast. Reconstr. Surg.*, 114 (2): 411-20. 2004.
- 6- Ulkur E., Acikel C., Eren F. and Celikoz B.: Use of dorsal ulnar neuro-cutaneous island flap in the treatment of chronic postburn palmar contractures. *Burns*, 31 (1): 99-104, 2005.
- 7- Karacalar A. and Ozcan M.: Preliminary report: The distally pedicled dorsoulnar forearm flap for hand reconstruction. *Br. J. Plast. Surg.*, 52: 453-7, 1999.
- 8- Antonopoulos D., Kang N.V. and Debono R.: Our experience with the use of the dorsal ulnar artery flap in hand and wrist tissue cover. *J. Hand Surg.*, 22: 739-44, 1997.
- 9- Thatté R.L., Gopalakrishina A. and Prasad S.: The use of deepithelized "turnover" flaps in the hand. *Br. J. Plast. Surg.*, 35: 293, 1982.
- 10- Yang J.Y., Tsai Y.C. and Noordhoff M.S.: The application of turn-over flaps to burn wounds. *Burns*, 12: 115-21, 1985.
- 11- Lai C., Lin S., Yang C. and Chou C.: The adipofascial turn-over flap for complicated dorsal skin defects of the hand and finger. *Br. J. Plast. Surg.*, 44: 165-9, 1991.
- 12- Lai C., Lin S., Chou C. and Tsai C.: Clinical application of adipofascial turn-over flaps for burn wounds. *Burns*, 19: 73-6, 1993.
- 13- Costa H. and Soutar D.S.: The distally based posterior interosseous flap. *Br. J. Plast. Surg.*, 41: 221-7, 1988.
- 14- Costa H., Comba A., Martins A., Rodrigues J., Reis J. and Amarante J.: Further experience with the posterior interosseous flap. *Br. J. Plast. Surg.*, 44: 449-55, 1991.
- 15- Amarante J.: Pedicle fasciocutaneous and adipofascial flaps. Severe traumatic defects of the upper limb. Dunitz-Taylor and Francis group, 2003.
- 16- Testut L. and Latarjet A.: *Tratado de Anatomia Humana*. Barcelona Salvat, 1954.